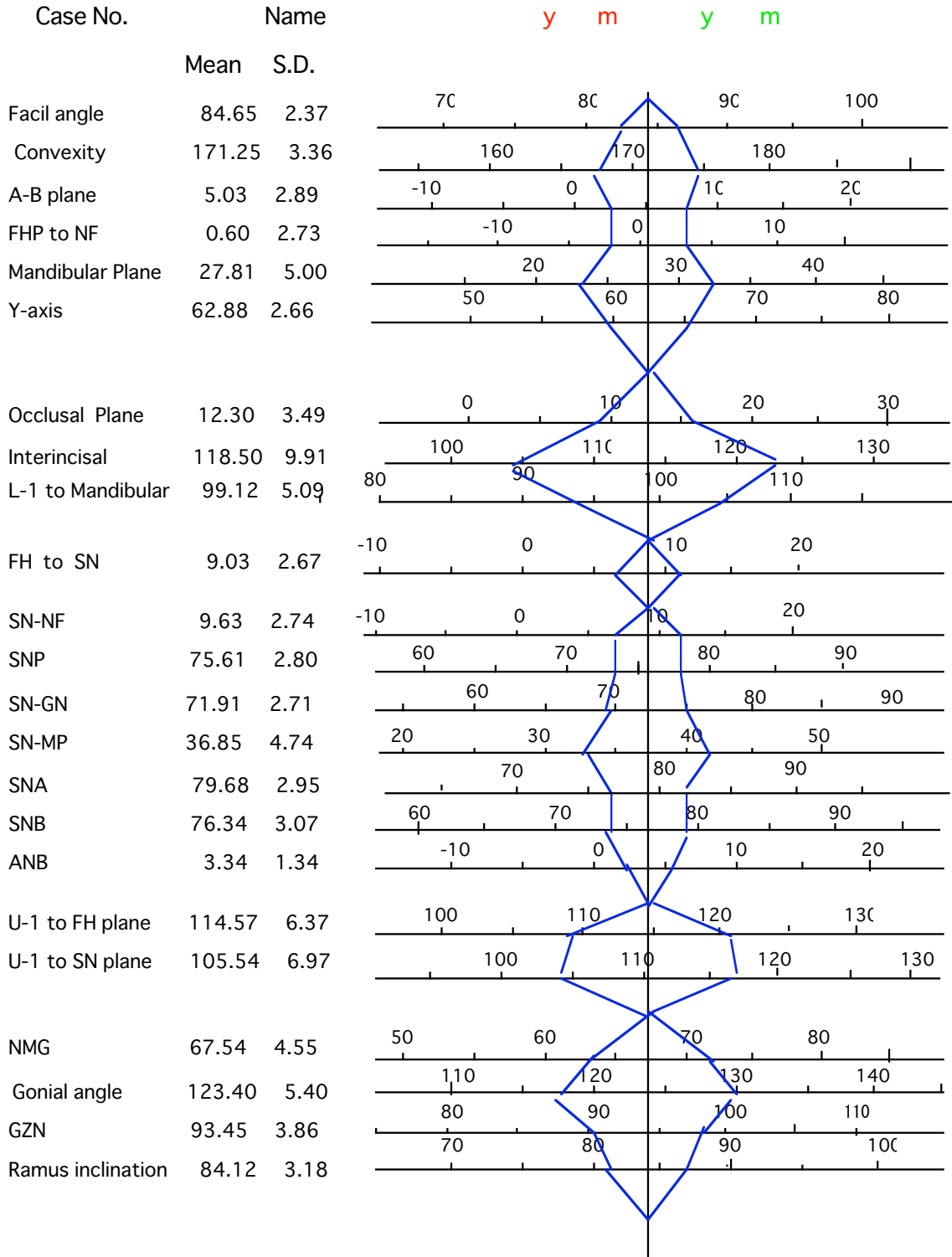


LATERAL CEPHALOMETRIC ANALYSIS

Female Stage 5

(Mid Mixed Dent. 10y8m±11m)



Standard by Japanese Society of Pediatric Dentistry '95